



# “What are these bumps in my groin?”

Benjamin Barankin, MD, FRCPC

A 21-year-old sexually-active male presents with asymptomatic, flesh-coloured papules in his pubic region. They appear to be spreading and he is concerned for himself and his partner. He has a history of migraines for which he takes ibuprofen and a triptan medication.

## 1. What is the most likely diagnosis?

- Genital warts
- Genital herpes
- Seborrheic keratoses
- Angiokeratomas
- Skin tags

## 2. Which strain of this condition should you be most worried about?

- 6
- 11
- 16
- 33
- 35

## 3. How could you manage these lesions?


- Excision
- Cryosurgery
- Electrosurgery
- Topical imiquimod
- All of the above

Genital warts are due to the double-stranded HPV of which more than 90 strains have been identified. Approximately 90% of the strains are HPV-6 and HPV-11 which have minimal neoplastic potential. Another 15 strains have increased potential for genitourinary neoplastic

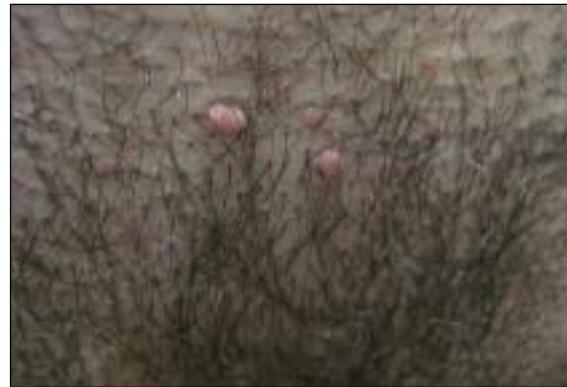

Figure 1. Papules in the pubic region.

conversion, particularly HPV-16 and HPV-18. Many individuals have co-existence of several strains of HPV. Following acquisition, a latency period of months to years may take place. This most commonly sexually transmitted disease has the highest prevalence in the 17- to 33-year-old bracket, with annual incidence of 1%. Based on the history and physical examination, consider testing for other sexually transmitted infections such as gonorrhoea, chlamydia, syphilis and HIV.

Typical treatments include destructive therapies such as cryotherapy, electrodesiccation, curettage, surgical excision or CO<sub>2</sub> laser ablation. There are also immune-based therapies such as topical imiquimod, topical 5-fluorouracil and acid application (e.g., trichloroacetic acid). Now that HPV vaccines are being implemented (targeting HPV-6, 11, 16, 18), there will likely be a dramatic decrease in genital warts and genitourinary cancer. 

Answers: 1-a; 2-c; 3-e

Dr. Barankin is a Dermatologist practicing in Toronto, Ontario.